

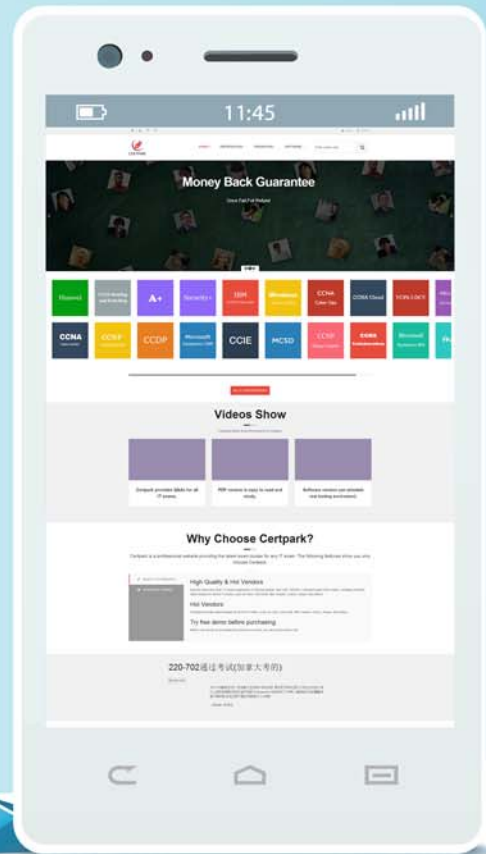
CERTPARK



QUESTION & ANSWER

CERTPARK.COM

Accurate Study Guides,
High Passing Rate!
provides update
free of charge
in one year!



Exam : MCQS

**Title : Multiple-choice questions
(MCQS) Prometric MCQS
for general practitioner (GP)
Doctor**

Version : DEMO

1. A 38-year-old man presents with acute infection of skin in the leg. Diagnosis of cellulitis has been made. What should be prescribed?

- A. Ceftriaxone + Flucloxacillin
- B. Vancomycin + Metronidazole
- C. Metronidazole + Erythromycin
- D. Ceftriaxone + Terbinafine
- E. Penicillin + Flucloxacillin

Answer: E

Explanation:

Penicillin + Flucloxacillin. Cellulitis is usually caused by bacteria, such as staphylococci or streptococci, which are commonly present on the skin. So Penicillin + Flucloxacillin should be given.

2. A 28-year-old man presents with a 2 hours' history of rapid palpitations. He feels a little light headed but is otherwise well. Exam: pulse=170 bpm and regular, BP=100/68 mmHg. He has had 2 similar episodes in the past. What is the most likely disturbance?

- A. SVT
- B. VF
- C. A-fibrillation
- D. VT
- E. Ventricular-ectopic

Answer: A

Explanation:

Palpitation, light headedness with a tachycardia of 170 bpm that is regular are most likely a SVT.

3. A 29-year-old lady who is a bank manager is referred by the GP to the medical OPC due to a long history of pain in the joints. An autoimmune screen result showed smooth muscle antibodies positive. What is the most appropriate investigation?

- A. Jejunal biopsy
- B. Thyroid function test
- C. Liver function test
- D. Serum glucose
- E. ECG

Answer: C

Explanation:

Autoimmune hepatitis. Definitive investigation is liver biopsy. Steroid [start with high dose prednisolone]. Azathioprine is commonly added with steroid to reduce its dose as it has more side effects than azathioprine.

4. A 65-year-old man presents with significant weight loss and complains of cough, SOB and chest pain. Exam: constricted, drooping of left eyelid.

What is the most likely diagnosis?

- A. Thoracic outlet syndrome
- B. Cervical rib
- C. Bronchogenic carcinoma
- D. Pancoast tumor

E. Pneumonia

Answer: D

Explanation:

Pancoast tumor. Pancoast tumour is the apical lung cancer that is associated with destructive lesion thoracic inlet and involvement of the brachial plexus and cervical sympathetic nerves (the stellate ganglion) ie horner's syndrome.

5.A 26-year-old political refugee has sought asylum in the UK and complains of poor concentration. He keeps his family whom he saw killed in a political coup. He is unable to sleep and feels hopeless about his survival. But he is afraid to go out.

What is the most likely diagnosis?

A. PTSD

B. Acute stress disorder

C. OCD

D. Social phobia

E. GAD

Answer: A

Explanation:

PTSD. Keep getting thoughts of his family disaster, insomnia, to avoid similar circumstances he is out these are suggestive of PTSD.